



## PATIENT

Buddy Hrabal

## SPECIES

Canine

## BREED

Yorkie Mix

## SEX

MN

## AGE

13yr

## WEIGHT

12.8

## INTERPRETED BY

R. McKenzie Daniel,  
DVM, DABVP  
(Canine and Feline)

## IMAGING PERFORMED BY

Marco Lichfield

## HOSPITAL NAME

Sova Animal Hospital

## REFERRING VET

Dr Ammeraal

## INVOICE

24014

## DATE

02/27/2026

## PRESENTING CLINICAL SIGNS

- Pet urinating more per owner can't hold it in, also straining when urinating and defecating, no blood noted.
- Abnormal PE/Chem/CBC/UA Results: ALKP 372, B/C ratio 34, LYMPHS 34%, NEUT 56%, fecal neg, UA showed blood trace, RBC 4-10

## LIMITED ULTRASONOGRAPHIC EXAMINATION OF THE ABDOMEN

### Urinary System

The urinary bladder was normal in size and tone. A non-homogenous focally mineralized mass was present occupying the majority of the urinary bladder lumen, measuring ~ 3 cm in diameter. Minimal anechoic urine was present. No overt obstruction to urine outflow. The trigone, cystourethral junction, and visible pelvic urethra to a depth of 3 cm exhibited normal thickness and tone.

Normal size and margination were present in the kidneys. A normal 1:3 cortex / medulla ratio was maintained. The medulla and cortices were uniform in texture with some increased echogenicity and loss of corticomedullary symmetry and definition expected for the age of the patient. No evidence of pelvic dilation was present. No evidence of right/left hydroureter. The left kidney measured 4.3 cm in length. The right kidney measured 4.5 cm in length.

The residual prostate appeared normal and free of pathology measuring 0.8 cm in diameter.

## ULTRASONOGRAPHIC FINDINGS

### Primary

- Mineralized urinary bladder mass -consistent with neoplasia, i.e. transitional cell carcinoma
- Normal residual prostate and visible proximal urethra
- Age-related renal changes

## INTERPRETATION OF THE FINDINGS & FURTHER RECOMMENDATIONS

A screening BRAF assay may be considered for correlation. No obvious visualized regional lymphatic metastasis.



**PATIENT**

Buddy Hrabal

**SPECIES**

Canine

**BREED**

Yorkie Mix

**SEX**

MN

**AGE**

13yr

**WEIGHT**

12.8

**INTERPRETED BY**

R. McKenzie Daniel,  
DVM, DABVP  
(Canine and Feline)

**IMAGING PERFORMED BY**

Marco Lichfield

**HOSPITAL NAME**

Sova Animal Hospital

**REFERRING VET**

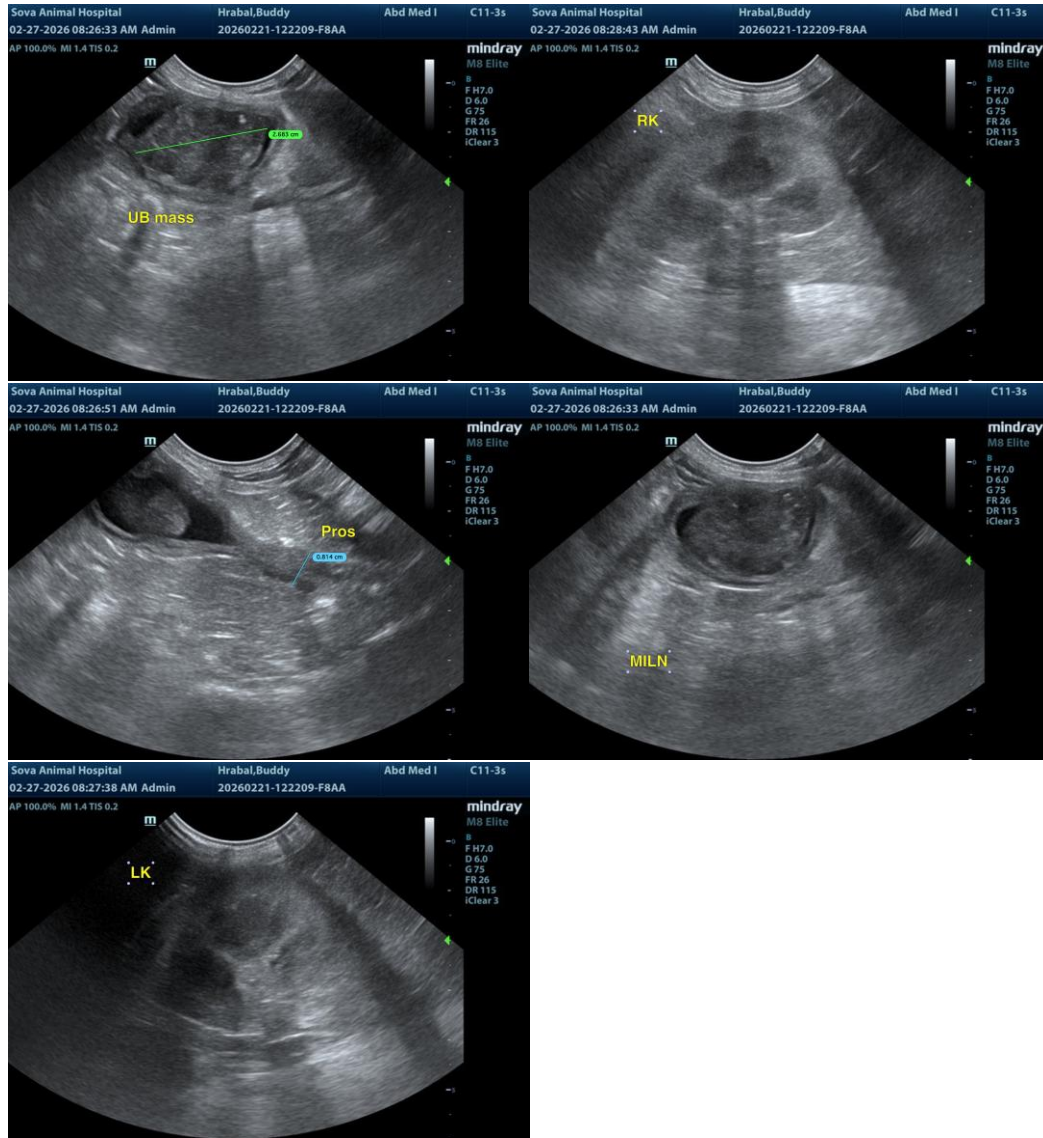
Dr Ammeraal

**INVOICE**

24014

**DATE**

02/27/2026



The information and recommendations provided are based on the images presented by the referring veterinarian/sonographer. No evaluation can be communicated regarding pathology that was not visible in the image/video clips provided.

Thank you for this referral. If the clinical or image interpretation does not parallel your findings or if I can be of any further assistance, please contact me.

R. McKenzie Daniel, DVM, DABVP (Canine/Feline Practice)  
[info@sonopath.com](mailto:info@sonopath.com)